

## Peritoneal membrana baęlı sol paraduodenal herni; olgu sunumu

### Abstract

Paraduodenal hernia is a rare cause of small-bowel obstruction. It comprises 53% of internal hernias and occurs three times more frequently on the left side. A 23 year-old man was admitted to our hospital with a history of recurrent, and colicky umbilical and left-upper abdominal pain. He was misdiagnosed during his first attack one year ago and he had been treated for familial Mediterranean fever by colchicine 0.5 mg twice daily. Here we report a case of an unusual paraduodenal hernia formed by a peritoneal membrane between the transverse and descending colon.

Key words: **Ileus; Internal hernia; Paraduodenal hernia.**

### Özet

Paraduodenal herni, ince barsak tıkanıklılıęını nadir bir nedendir.İnternal hernilerin %53'nü oluşturur ve sol tarafta 3 kat fazla gözükür. Yirmi üç yaşında erkek olgu umbilikal ve sol üst kadranda tekrarlayan ve kolik tarzda karın ağrıları nedeniyle hastanemize başvurdu. Olgu 1 yıl önce benzer ağrılar nedeniyle ailesel akdeniz ateşi tanısı alıp, kolçisin tedavisi almış. Biz, transvers ve inen kolon arasında peritoneal membrana baęlı oluşan paraduodenal herni vakasını sunuyoruz.

Anahtar kelimeler: **İleus; İnternal herni; Paraduodenal herni.**

Submitted : March 08, 2008  
Revised : July 18, 2008  
Accepted : December 15, 2008

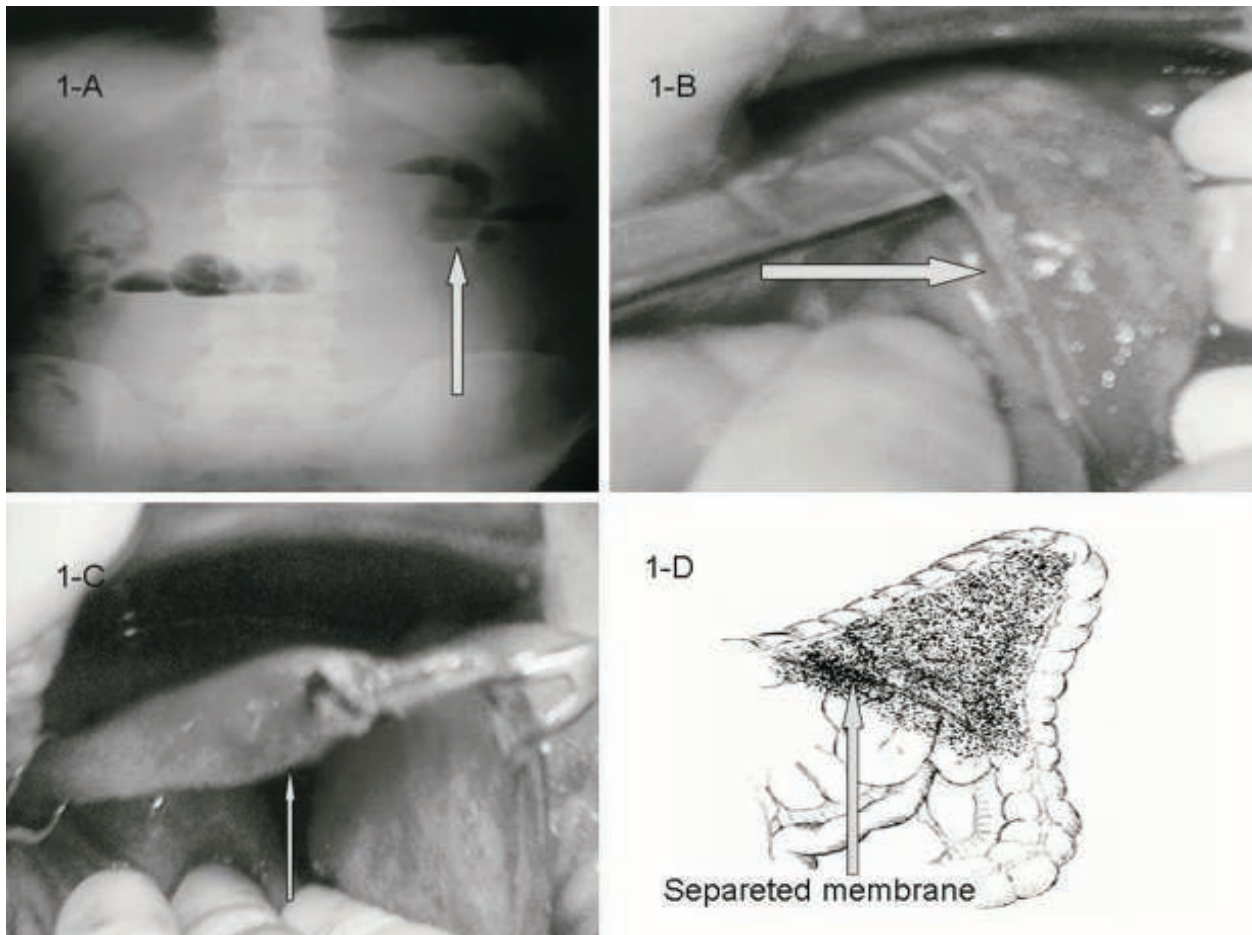
### Introduction

Left paraduodenal hernia resulting from abnormal rotation of the midgut in the course of embryonic development is the most common form of congenital internal hernia (1). Internal herniation of the small bowel is a relatively scarce reason of intestinal obstruction. Paraduodenal hernia represents the major subclassification and account for 53% of all internal hernias (2). It may be discovered as an incidental finding at laparotomy or may be the cause of acute small bowel obstruction which can result in strangulation and perforation (2). The clinical symptoms of paraduodenal hernia may be intermittent and nonspecific. The preoperative diagnosis of a paraduodenal hernia is difficult (3). Different diagnostic imaging modalities have been used for the diagnosis of paraduodenal hernias. We report a case of intestinal

obstruction caused by entrapment of the proximal jejunum in an unusually formed paraduodenal sac which was formed by abnormal peritoneal membrane between the transverse and the descending colon.

### Case Report

A 23-year-old man was admitted to the emergency department for the investigation of recurrent and intermittent colicky umbilical pain associated with nausea and vomiting. He had no previous history of abdominal surgery. On physical examination, umbilical and left-upper abdominal tenderness and mild distention were noted. Bowel sounds were hyperactive. There was no stool on rectal examination. Blood analysis, urine analysis showed no abnormalities, except for leukocytosis of 15 900/ml. Plain abdominal X-ray showed air-liquid level



**Picture 1.** Plain abdominal X-ray showed air-fluid levels of the small intestinal loop in the umbilical and the left upper abdomen (a). Intraoperative view, an edematous intestinal loop is herniated into a mesocolic fossa formed by an unusual peritoneal membrane between the transverse (b) and descending colon (c). Schematic illustration of operative findings (d).

of a small intestinal segment on umbilical and left-upper abdominal quadrants (Picture 1a). Abdominal ultrasonography (USG) was normal.

He described similar episodes of pain several times in the last year, but the pain resolved spontaneously each time. He was admitted to another emergency department two months ago. His pain was initially thought to have been caused by Familial Mediterranean Fever (FMF). He was prescribed colchicine 0.5 mg twice daily, but he discontinued the medication after 2 months because his symptoms did not resolve. On the present admission, his fibrinogen level was normal (1.98mg/dl). After, radiologic evaluation, and abdominal examination, we performed an emergency laparotomy, with the possibility of intestinal obstruction. On laparotomy, the proximal small intestine (approximately 60 cm of jejunum) was found to be entrapped and strangulated by the hernia, which consisted of a separated peritoneal sac between the transverse and descending colon (Picture 1b). The sac was surrounded by descending-transverse mesocolon, entering the Landzert fossa through an opening just under the inferior mesenteric vessels. The small intestine bowel was easily reduced from the sac manually and there were no ischemic changes. Resection of the peritoneal sac performed (Picture 1c) and the postoperative course was uneventful. He was discharged on postoperative day 3.

### Discussion

Paraduodenal hernia is a rare condition in which the small bowel loops are herniated into an unusual fossa in the periduodenal area. Paraduodenal hernia has been reported to be the most common type of internal hernias (4, 5). There are two types of hernias, which have been classified according to their site, left and right paraduodenal hernias. In cases of paraduodenal hernia, approximately 72% occur on the left side (6, 7). Several fossae have been described to be involved in left paraduodenal hernia, including the superior duodenal fossa, the fossa of Treitz, the fossa of Waldeyer, the fossa of Brosike, and the fossa of Landzert, although the importance of these fossae in the induction of paraduodenal hernia should be questioned (7). The most common type of left paraduodenal hernia originates in the fossa of Landzert, which is present in approximately 2% of autopsies (3). The pathogenesis of paraduodenal hernia is unclear. It is now generally accepted that left paraduodenal hernia is congenital in origin and is caused at the right time midgut rotation by invagination of the small bowel into an avascular, and therefore an supported

segment of the left mesocolon (6). Paraduodenal hernia can be asymptomatic and diagnosed incidentally at laparotomy. The most common presentation is acute small bowel obstruction with recurrent vague abdominal pain. The majority of patients have history of chronic digestive complaints such as colicky abdominal pain, fullness, vague and nausea (7). In our patient, although the laboratory findings were inconclusive, his clinical picture was thought to be in accordance with FMF and he was prescribed unnecessary treatment for FMF in another emergency department.

Paraduodenal hernia carry about a 50% lifetime risk of incarceration, leading to bowel obstruction and strangulation and for this reason should be treated when found. Although the left paraduodenal hernia is congenital, most patients are recognized between the third and fourth decades of life, and the mean age at the time of diagnosis is 29 years (range: 2-74). Male to female ratio is reported to be 3:1 in English literature (6). Whereas our patient is a 23 year-old man.

The correct diagnosis preoperative is difficult in paraduodenal hernia. Plain abdominal X-ray may demonstrate the accumulation of dilated loops of small bowel in one area and air-liquid levels of a small bowel segment. This feature was also apparent in our patient. An upper gastrointestinal series with small bowel follow-through demonstrates contrast-filled loops of small bowel clustering over the left upper aspect of the abdomen. Abdominal USG may also aid in the diagnosis of paraduodenal hernia (1). Abdominal computed tomography (CT) is used in the diagnosis of paraduodenal hernia and has a high diagnostic accuracy in defining the possible etiology. The CT criteria for the diagnosis of paraduodenal hernia were described as a clustering of small-bowel loops, a sac-like mass with encapsulation at or above the ligament of Treitz, a mass on the posterior stomach wall, and mesenteric vessel abnormalities (9).

The principles of surgical treatment of paraduodenal hernia are reduction of hernia contents and obliteration of the hernia defect by simple closure or incision of the sac in the avascular plane, by open or laparoscopic surgery (2, 5). In our patient, the ventral wall of the hernia sac was formed by an abnormal peritoneal membrane between the transverse and the descending colon (Picture 1d). Similar cases were reported, with the left paraduodenal hernia formed by adhesion (3, 4). We reduced the sac

contents and assessed the viability of the intestinal segment and resection of the sac was performed.

In conclusion, the clinical findings in some patients with a paraduodenal hernia may be nonspecific and misleading. The diagnosis is often made at surgery for an acute condition, or incidentally. A correct preoperative diagnosis may also help surgical planning in patients with altered anatomy, and assist in the differential diagnosis of other defined rare internal hernias.

## References

1. Huang YM, Chou AS, Wu YK, et al. Left paraduodenal hernia presenting as recurrent small bowel obstruction. *World J Gastroenterol* 2005; 11: 6557-6559.
2. Cingi A, Demirkalem P, Manukyan MM, Tuney D, Yegen C. Left-sided paraduodenal hernia: Report of a case. *Surg Today* 2006; 36: 651-654.
3. Nishida T, Mizushima T, Kitagawa T, Ito T, Sugiura T, Matsuda H. Unusual type of left paraduodenal hernia caused by a separated peritoneal membrane. *J Gastroenterol* 2002; 37: 742-744.
4. Hirasaki S, Koide N, Shima Y, et al. Unusual variant of left paraduodenal hernia herniated into the mesocolic fossa leading to jejunal strangulation. *J Gastroenterol* 1998; 33: 734-738.
5. Kurachi K, Nakamura T, Hayashi T, et al. Left paraduodenal hernia in an adult complicated by ascending colon cancer: A case report. *World J Gastroenterol* 2006; 12: 1795-1797.
6. Tong RS, Sengupta S, Tjandra JJ. Left paraduodenal hernia: case report and review of the literature. *ANZ J Surg* 2002; 72: 69-71.
7. Berardi RS. Paraduodenal hernias. *Surg Gynecol Obstet* 1981; 152: 99-110.
8. Uematsu T, Kitamura H, Iwasawa M, et al. Laparoscopic repair of a paraduodenal hernia. *Surg Endosc* 1998; 12: 50-52.
9. Blachar A, Federle MP, Dodson SF. Internal hernia: Clinical and imaging findings in 17 patients with emphasis on CT criteria. *Radiology* 2001; 218: 68-74.